

Necrotizing Fasciitis of the Breast

Sir:

Necrotizing fasciitis of the breast is a rare entity, with only a handful of cases reported in the literature.¹⁻³ The robust blood supply of the breast makes salvage possible if this condition is recognized early.

A 38-year-old woman with no comorbidities presented with a 1-week history of left breast pain, swelling, and fever. She was seen at another hospital and diagnosed with left breast cellulitis. Despite treatment with antimicrobial agents, her symptoms became progressively worse and she was transferred to our care. Figure 1 shows her physical findings at admission. Her laboratory parameters were as follows: white blood cell count, 26 cells/mm³; hemoglobin, 10.8 g/dl; sodium, 134 mM; creatinine, 2.1 mg/dl; glucose, 110 mg/dl; and C-reactive protein, 60 mg/liter (Laboratory Risk Indicator for Necrotizing Fasciitis score = 8) (Table 1). Magnetic resonance imaging demonstrated findings consistent with left breast necrotizing fasciitis, which was confirmed at debridement (Fig. 2). The necrotic fascia, nonviable skin, subcutaneous tissue, and small amount of breast parenchyma in the lower outer quadrant were excised. The remaining breast parenchyma was viable and thus preserved. A second look 24 hours later noted the wound to be clean, with no progression of the fasciitis. The wound was subsequently closed by secondary suture.

Necrotizing fasciitis of the breast usually necessitates mastectomy because of delayed diagnosis.¹⁻³ This condition has variously been misdiagnosed as cellulitis, abscess, and even inflammatory breast cancer. The cutaneous features of necrotizing fasciitis as the disease evolves from early to intermediate to late stages have previously been described.⁴ In the breast, however, because of the thicker tissue between the deep fascia and

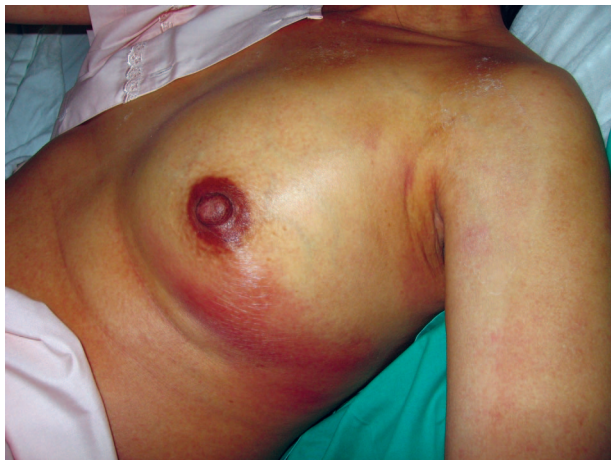

Fig. 1. Her left breast was swollen, warm, erythematous, and tender. Maximal tenderness and skin changes were noted over the lower outer quadrant of the breast.

Table 1. The Laboratory Risk Indicator for Necrotizing Fasciitis Score*

Variable	Points
C-reactive protein	
<150 mg/liter	4
>150 mg/liter	0
White blood cell count	
<15 cells/mm ³	0
15–25 cells/mm ³	1
>25 cells/mm ³	2
Hemoglobin level	
>13.5 g/dl	0
11–13.5 g/dl	1
<11 g/dl	2
Sodium level	
≥135 mM	0
<135 mM	2
Creatinine level	
≤1.6 mg/dl	0
>1.6 mg/dl	2
Glucose level	
≤180 mg/dl	0
>180 mg/dl	1

*The Laboratory Risk Indicator for Necrotizing Fasciitis (LRINEC) score was designed specifically to distinguish necrotizing fasciitis from other soft-tissue infections. This score was developed from a laboratory test commonly performed for the assessment of severe soft-tissue infection and widely available across different institutions. Six independent variables were identified and each gives a specific point toward the final score. The LRINEC score is calculated by summing the points assigned to each of the six variables that make up the score. A score of less than 6, 6 to 7, or 8 or higher is designated as low, intermediate, or high risk, respectively, for the presence of necrotizing fasciitis. We recommend early imaging or operative exploration for suspicious cases with a score of 6 or higher. (Adapted from Wong, C. H., Khin, L. W., Heng, K. S., Tan, K. C., and Low, C. O. The LRINEC (Laboratory Risk Indicator for Necrotizing Fasciitis) score: A tool for distinguishing necrotizing fasciitis from other soft tissue infections. *Crit. Care Med.* 32: 1535, 2004.)

the skin, cutaneous signs may not be apparent until the disease is well advanced, by which time the breast is not salvageable.

A high index of suspicion is, therefore, of paramount importance. Pain out of proportion to visible skin changes, swelling, and warm skin may be the only presenting complaints. The paucity of specific cutaneous signs early in the course of the disease makes early recognition very difficult in the breast when compared with other areas of the body. Diagnostic adjuncts that can help in early recognition of the disease are particularly helpful in this area of the body and should be an integral part of the assessment of suspicious cases. In this context, the Laboratory Risk Indicator for Necrotizing Fasciitis score is a valuable tool.⁵

Intraoperatively, an incision should be made down the pectoralis muscle over the area of maximal tenderness and most obvious skin involvement. The extent of infection can be delineated by bluntly probing the wound, and any area in which the deep fascia can be lifted off the underlying muscle is involved. The deep fascia must be excised completely. The skin, subcutaneous tissue, and breast parenchyma are progressively

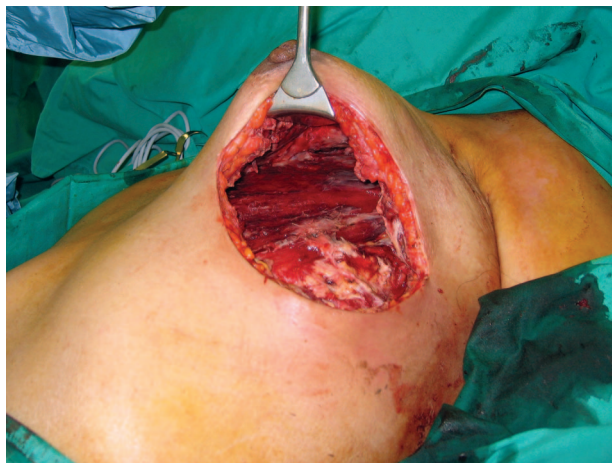


Fig. 2. A wide incision was made over the area of maximal tenderness. Necrotizing fasciitis was confirmed with necrotic fascia and copious "dishwater" pus. The involved fascia extended from the second rib to the sixth rib and from the sternal border to the anterior axillary fold. The necrotic fascia, nonviable skin, and subcutaneous tissue were excised completely. The pectoralis muscle was healthy and the overlying breast parenchyma was viable and therefore preserved.

cut back sharply from the edges of the incision and from the deep aspect of the wound until healthy, uninfected tissue with good bleeding is encountered. The aim of surgery must be to completely remove all infected tissue at the first debridement.

DOI: 10.1097/PRS.0b013e318186cd92

Chin-Ho Wong, M.R.C.S.

Bien-Keem Tan, F.R.C.S.

Department of Plastic, Reconstructive, and
Aesthetic Surgery
Singapore General Hospital
Singapore

Correspondence to Dr. Wong
Department of Plastic, Reconstructive, and
Aesthetic Surgery
Singapore General Hospital
Outram Road
Singapore 169608
wchinho@hotmail.com

DISCLOSURE

The authors did not receive any funding for this work and declare that they have no conflict of interest regarding this article.

REFERENCES

1. Rajakannu, M., Kate, V., and Ananthakrishnan, N. Necrotizing infection of the breast mimicking carcinoma. *Breast J.* 12: 266, 2006.
2. Nizami, S., Mohiuddin, K., Mohsin-e-Azam, Zafar, H., and Memon, M. A. Necrotizing fasciitis of the breast. *Breast J.* 12: 168, 2006.

3. Shah, J., Sharma, A. K., O'Donoghue, J. M., Mearns, B., Johri, A., and Thomas, V. Necrotizing fasciitis of the breast. *Br. J. Plast. Surg.* 54: 67, 2001.
4. Wong, C. H., and Wang, Y. S. The diagnosis of necrotizing fasciitis. *Curr. Opin. Infect. Dis.* 18: 101, 2005.
5. Wong, C. H., Khin, L. W., Heng, K. S., Tan, K. C., and Low, C. O. The LRINEC (Laboratory Risk Indicator for Necrotizing Fasciitis) score: A tool for distinguishing necrotizing fasciitis from other soft tissue infections. *Crit. Care Med.* 32: 1535, 2004.

W-Shaped Mammary Gland Resection for Reduction Mammoplasty

Sir:

We reported the dermal bra technique for reduction mammoplasty and correction of ptosis in 2003.¹ The W-shaped mammary gland resection technique has been applied clinically as a modification of this technique since 2001, based on the following anatomical features: the blood supply of the inferior gland is more sufficient than the superior gland,² and the anterior and lateral branches of intercostal nerves run anteroinferiorly.

A W-shaped glandular resection was performed on the upper part of the breast. The starting point was located on the sternum edge of the fourth intercostal space. The cutting line ran inferolaterally, reversed superiorly at the level of the nipple, and then ran along the edge of the dermal bra. The lateral lowest point was at the level of the nipple. The endpoint was at the intersection of the anterior axillary line and the fourth intercostal space. In very large breasts, the medial lowest point might shift inferiorly, and care should be taken to avoid injuring the deep branches of the lateral subcutaneous branches of the fourth intercostal nerve. After resection of the gland was finished, the remaining gland presented three peaks (A, B, and C glandular flaps from medial to lateral).

The B and C flaps were rotated medially. The B flap was sutured to the A flap, and the C flap was sutured to B. Thus, the base of the breast was reduced and a projective breast mound was created. If the dermal bra was not sufficient to cover the remaining gland, a knitted polypropylene mesh could be used as a substitute for the dermal bra as described by Goes.

We studied 38 patients (76 breasts) ranging in age from 16 to 55 years, whose preoperative breast volume ranged from 686 to 1820 mm³ and whose weight of the gland excised ranged from 348 to 1475 g. The short-term complications included postponed wound healing in three breasts, fat necrosis in two breasts, subcutaneous fluid accumulation in two breasts, and no response to pressure of the nipple-areola and no sensitivity to touch in one breast.

Twenty-seven patients were followed up from 6 to 24 months, and 25 patients acquired satisfactory appearance. Only one patient presented a slightly wider scar around the areola and mild asymmetry. The secondary treatment was performed 1 year later and a satisfactory result was acquired. One patient who had immediately