

# Facial Soft-Tissue Spaces and Retaining Ligaments of the Midcheek: Defining the Premaxillary Space

Chin-Ho Wong, M.R.C.S.(Ed.),  
F.A.M.S.(Plast. Surg.)

Bryan Mendelson,  
F.R.C.S.(Ed.),  
F.R.A.C.S., F.A.C.S.

Singapore and Toorak,  
Victoria, Australia



**Background:** This anatomical study was undertaken to define the soft-tissue spaces, retaining ligaments, and their relations in the midcheek.

**Methods:** Sixty fresh hemifaces were dissected. The retaining ligaments and facial spaces were defined and their dimensions recorded. The course of the key vessels and branches of the facial and infraorbital nerves were defined and their anatomical relations noted.

**Results:** The preseptal and prezygomatic spaces underlie the lid-cheek and malar segments of the midcheek. A previously undocumented soft-tissue space, the premaxillary space, was found to underlie the nasolabial segment. The retaining ligaments of the midcheek are the tear trough–orbicularis retaining ligament complex in the upper midcheek and the zygomatic and maxillary ligaments in the lower midcheek. The tear trough–orbicularis retaining ligament complex separates the preseptal space above from the prezygomatic and premaxillary spaces below. Facial nerve branches in the midcheek are closely associated with the zygomatic ligaments located outside the lower boundary of the prezygomatic space and are protected so long as the dissection is kept within this space. The infraorbital nerve is protected by the floor of the premaxillary space, formed by the levator labii superioris and, at the inferior boundary of the space, by the close relation with the maxillary ligaments.

**Conclusions:** This study completely defined the spaces and retaining ligaments of the midcheek. Knowledge of this anatomy is key to safe and atraumatic suborbicular dissection for effective midcheek lifts. (*Plast. Reconstr. Surg.* 132: 49, 2013.)

The midcheek is structurally a highly complex area of anatomy that separates the orbital cavity above from the oral cavity below.<sup>1,2</sup> Even though the midcheek appears uniform in youth, it in fact has two distinct parts: one that directly overlies bone (formed by the body of the zygoma laterally and the maxilla medially) and one that is unsupported, where it overlies the orbital cavity above and oral cavity below the midcheek skeleton. Accordingly, there is a limited area of “available” midcheek bony platform for the support of the overlying soft tissues. Furthermore, the complex movements of the midcheek required during facial expression mandates that the midcheek soft tissues be delicately balanced between the

*simultaneous needs for mobility and stability.* As a result, the anatomy here is highly compacted and *complex.*

The retaining ligaments of the face are responsible for binding the soft-tissue layers of the face to the underlying facial skeleton, from the dermis to the periosteum where bone is available or else to the deep fascia of the underlying

**Disclosure:** *The authors have no financial interest to declare in relation to the content of this article.*

Supplemental digital content is available for this article. Direct URL citations appear in the text; simply type the URL address into any Web browser to access this content. Clickable links to the material are provided in the HTML text of this article on the *Journal's* Web site ([www.PRSJournal.com](http://www.PRSJournal.com)).

*From W Aesthetic Plastic Surgery and the Center for Facial Plastic Surgery.*

*Received for publication October 5, 2012; accepted January 11, 2013.*

*Copyright © 2013 by the American Society of Plastic Surgeons*

DOI: 10.1097/PRS.0b013e3182910a57

structures, such as the parotid and the muscle of mastication.<sup>3,4</sup> Motor and sensory nerves that pass from deep to superficial to innervate their target structures transition to the superficial fascia predictably in close association with these retaining ligaments, as they provide areas of relative stability for protection of these vital structures. In between these retaining ligaments are located the facial soft-tissue spaces.<sup>2</sup> Conceptually, these are gliding planes that function to facilitate mobility of the superficial fascia over the deep fascia as well as movement of the orbital part of the superficial fascia independent of the perioral part, and vice versa. The recognized soft-tissue spaces in the upper and lower face are the temporal and pre-masseter spaces, respectively.<sup>5,6</sup>

With aging, the midcheek “fragments” into three distinct segments: the lid-cheek, malar, and nasolabial segments.<sup>1</sup> The development of these segments is explained on an anatomical basis by the inherent mobility and *eventual laxity* over the roof of the soft-tissue spaces (resulting in surface bulges) in contrast to the relative fixation at the boundaries provided by the retaining ligaments of the midcheek (creating surface troughs). The preseptal and prezygomatic spaces have previously been defined and their anatomical implications elucidated.<sup>7,8</sup> In contrast, the anatomy of the medial midcheek, involving the nasolabial segment over the maxilla, has not been similarly defined. Specifically, the presence of a significant soft-tissue space, with associated retaining ligaments and nerves, is predicted based on the mobility and laxity that develops here. This study is a comprehensive investigation of the midcheek anatomy to define all the soft-tissue spaces and retaining ligaments of the midcheek.

## MATERIALS AND METHODS

The surgical anatomy of the midcheek was investigated in 60 fresh hemifaces of 30 cadaver heads. There were 17 male and 13 female hemifaces with a mean age of 57 years. Dissection was performed under 2.5× loupe magnification. Using a “through the facial soft-tissue spaces” dissection approach, the surgical spaces were entered and developed by blunt dissection to define their boundaries to their full extent. The retaining ligaments, located within the boundaries of these spaces, were then defined and carefully released to determine their precise location and relationships with the related soft-tissue spaces. The zygomatic and buccal branches of the facial nerve that innervate the orbicularis were traced from the

parotid to the orbicularis oculi, noting in particular their relations to the retaining ligaments. The course and relations of the infraorbital nerve were also investigated. The dimensions of the origins of the retaining ligaments were measured using a caliper, and photographic records were taken of all the dissections.

## RESULTS

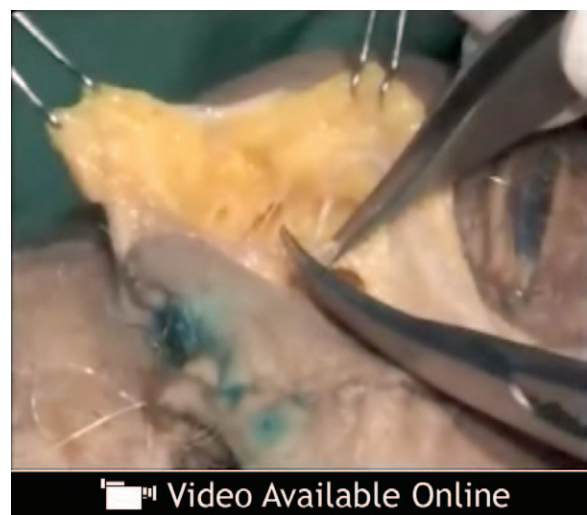**See Video 1, Supplemental Digital Content 1,** which demonstrates the spaces, retaining ligaments, and relations of the nerves of the midcheek, <http://links.lww.com/PRS/A740>.

### The Tear Trough–Orbicularis Retaining Ligament Complex

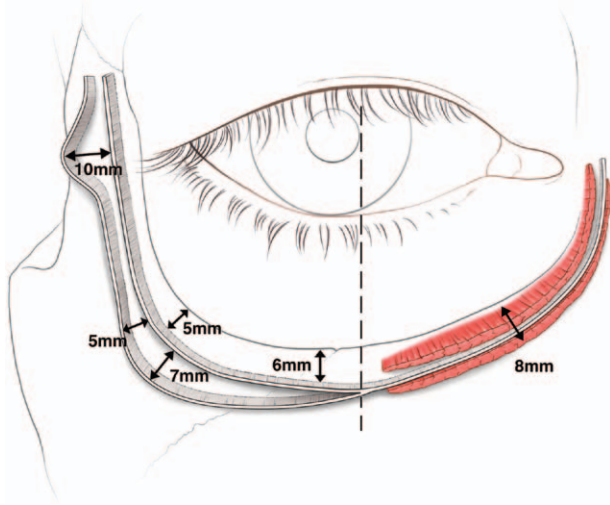
The tear trough–orbicularis retaining ligament complex is the key retaining ligament of the midcheek. The anatomy of this ligamentous system was detailed in our earlier publication<sup>9</sup> (Fig. 1).

### Preseptal Space

This space within the structure of the lower lid largely overlies the orbital cavity. It is bounded inferiorly by the origins of the palpebral part of the orbicularis oculi medially and by the orbicularis retaining ligament laterally. Further laterally, at about the level of the lateral canthus, it is bounded by the lateral orbital thickening. This potential space under the orbicularis oculi readily “opens up” in submuscular lower eyelid blepharoplasties. The floor of the space is mainly



**Video 1.** Supplemental Digital Content 1 demonstrates the spaces and retaining ligaments of the midcheek. The relations of these spaces and retaining ligaments to the vital structures of the midcheek, nerves, and vessels are also demonstrated, <http://links.lww.com/PRS/A740>.



**Fig. 1.** The tear trough–orbicularis retaining ligament complex. The tear trough ligament continues laterally as the bilamellar orbicularis retaining ligament from the medial pupil line. The orbicularis retaining ligament in turn continues as the lateral orbital thickening at the level of the lateral canthus. The origins of the palpebral and orbital parts of the orbicularis oculi and the tear trough ligament located between them span a mean distance of 8 mm. The orbicularis retaining ligament is located several millimeters below the orbital rim. The upper and lower lamellae of the orbicularis retaining ligament are separated by a variable distance, as indicated in the diagram.

the orbital septum and it extends inferiorly for a short distance over the orbital rim. No structures pass within this space, which can be opened by blunt dissection to the arcus marginalis, and for a further short distance over the orbital rim (2 to 6 mm) to its inferior boundary. This space provides a bloodless, atraumatic access to the lower eyelid.

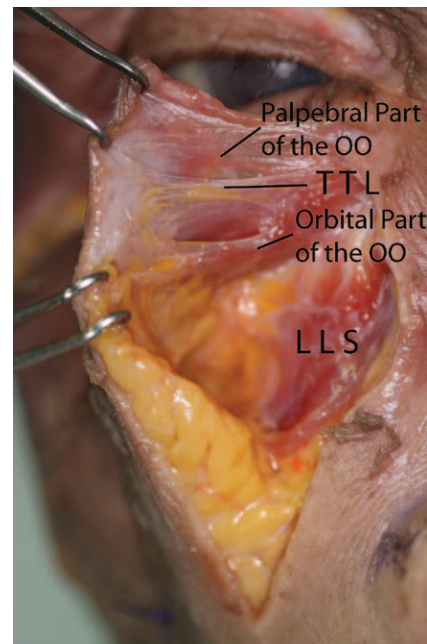
### Prezygomatic Space

This triangular space over the body of the zygoma is bounded superiorly by the orbicularis retaining ligament and inferiorly by the zygomatic ligaments. The floor of the prezygomatic space is covered by a layer of preperiosteal fat. Located in the floor of the prezygomatic space are the origins of the zygomaticus major and minor (which may be located up to halfway up the floor of the space). The orbital part of the orbicularis oculi forms the roof of the space. Medially, at about the midpupil line, its upper (orbicularis retaining ligament) and lower boundaries merge. This is the anatomical basis for the convergence of the palpebromalar groove above and the midcheek groove below and the tear trough medially as an obliquely orientated “Y” groove on the midcheek.

### The Premaxillary Space

A soft-tissue space anterior to the maxilla was noted in the dissections and accordingly named the premaxillary space. This is a rectangular space that underlies the nasolabial segment of the midcheek. Similar to other soft-tissue spaces of the face, the premaxillary space is an avascular gliding plane lined by a membrane. The upper half of its roof is formed by the orbital part of the orbicularis oculi and the lower half is formed by the midcheek superficial musculoaponeurotic system. The floor of the space is formed by the levator labii superioris (Fig. 2). Its superior boundary is formed by the tear trough ligament, which itself is bounded by the origins of the palpebral and orbital parts of the orbicularis oculi off the maxilla cephalic and caudal to the ligament, respectively. The tear trough ligament and its associated orbicularis oculi origins separate the preseptal space above from the premaxillary space below.

The inferior boundary is extremely strong, being reinforced by a pair of broad, transversely orientated retaining ligaments. The ligaments, which are located at approximately the level of the alar base, insert into the uppermost part of the nasolabial fold. Each ligament has a mean length of 4 mm in the vertical dimension and 6 mm in



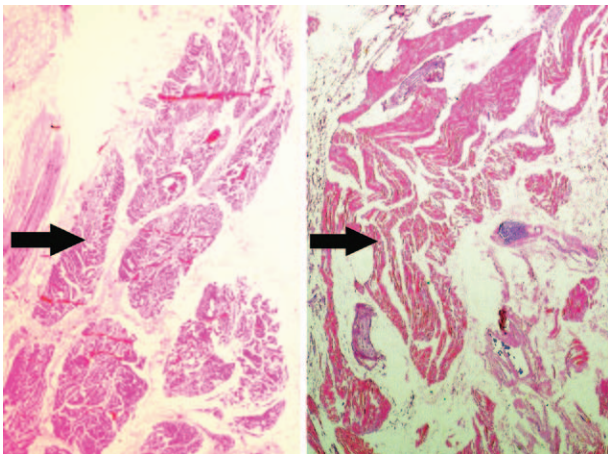
**Fig. 2.** The premaxillary space is a true facial soft-tissue space lined by a membrane. The levator labii superioris (LLS) forms the floor. Its superior boundary is formed by the tear trough ligament (TTL) sandwiched by the origins of the palpebral and orbital parts of the orbicularis oculi (OO).



the horizontal dimension, and a mean length of 28 mm from the maxilla to the dermis. These ligaments originate from the maxilla; accordingly, they are called the maxillary ligaments. As with the zygomatic ligaments, the maxillary ligaments are not continuous structures but consist of two main bundles of ligaments, with a gap between them for the levator labii superioris to pass into the upper lip. The ligament is extremely strong; when grasped with a hemostat, the weight of the entire head can be suspended off the ligament. These osteocutaneous ligaments, as with the zygomatic ligaments more laterally, are located at the last location available for stabilization of the perioral soft tissues to the skeleton before transitioning of the soft tissues located over the vestibule of the oral cavity. Histologically, the maxillary ligaments have features identical to those of the zygomatic ligaments, the most widely recognized osteocutaneous ligament in facial anatomy (Fig. 3). Medially, the premaxillary space is bounded by the nasal sidewall, the levator labii superioris alaeque nasi, and the nasalis. Its lateral boundary, located at the medial pupil line, is an area of loose areolar tissue about 5 mm wide. No ligaments are located here, and this area separates the premaxillary space from the tapered medial part of the prezygomatic space.

#### Relations of the Vessels and Nerve Branches to the Premaxillary Space

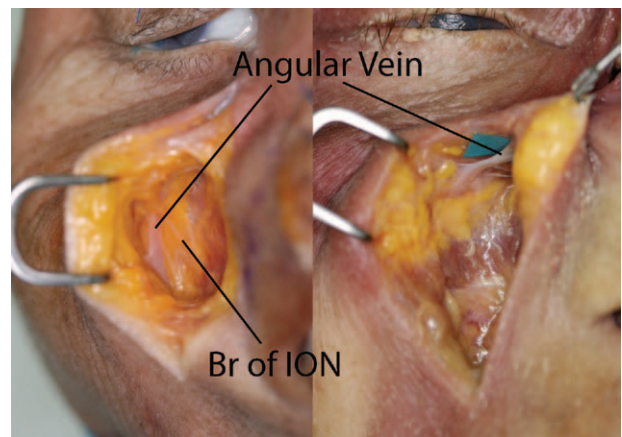
The angular vein runs in the lateral border of the premaxillary space. As it reaches the upper border of the space, it turns acutely medially in



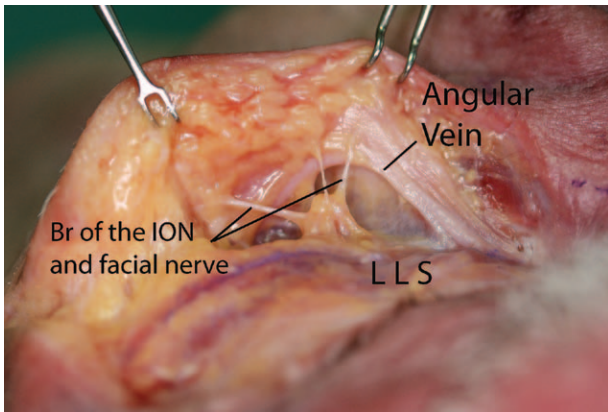
**Fig. 3.** Hematoxylin and eosin stain of the maxillary ligament at 40× magnification (*left*). Histologically, the maxillary ligament is composed of dense, strong bundles of collagen fibers (*arrow*) and looks identical to the zygomatic ligament (*right*), the most widely recognized osteocutaneous ligament in facial anatomy.

close association with the underside of the orbital part of the orbicularis as it arises from the maxilla. From here, the angular vein follows the gentle curvature of the origin of the orbital part of the orbicularis oculi to the medial canthus (Fig. 4). As it traverses the lateral border of the premaxillary space, a branch from the infraorbital nerve and branches from the zygomatic and buccal branches of the facial nerve pass from deep to superficial in close association with the angular vein to innervate the orbicularis oculi in the roof of the premaxillary space (Fig. 5). The angular artery runs in the medial border of the premaxillary space and when it reaches the superior boundary of the premaxillary space, comes to lie in close association and caudal to the angular vein. Also, with one or sometimes two nerve branches pass to the orbicularis in the roof of the premaxillary space.

The infraorbital nerve (V2) is the sensory nerve of the midcheek. The nerve is consistently located more medially than expected in the preperiosteal plane, 2 to 4 mm medial to the midpupil line at its longitudinal axis. This is because the axis of the infraorbital foramen is orientated inferomedially. The nerve therefore comes to lie in a more medial location immediately after it emerges from the foramen. The zygomatic and upper buccal branches of the facial nerve connect with the infraorbital nerve branches, forming a plexus of mixed sensory and motor nerves that then together innervate the target

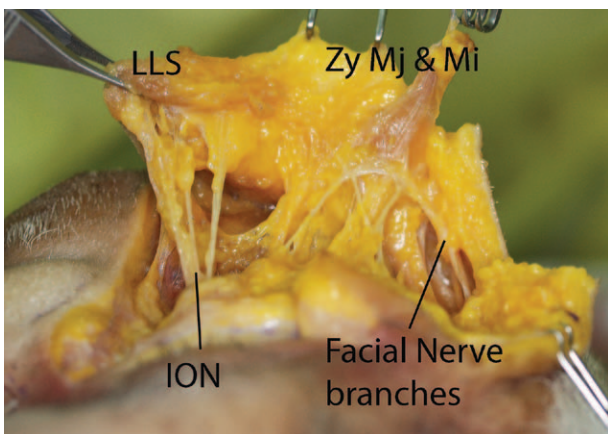


**Fig. 4.** The course of the angular vein within the lateral and upper boundaries of the premaxillary space. On the *left*, the sentinel vein is seen running cephalically in the lateral boundary of the premaxillary space, where it is in relation to a branch of the infraorbital nerve (*Br of ION*), which is medial to the vein. On reaching the upper boundary of the premaxillary space (*right*), the vein angles sharply to run horizontally on the underside of the orbital part of the orbicularis and it follows the origin of this muscle toward the medial canthus.

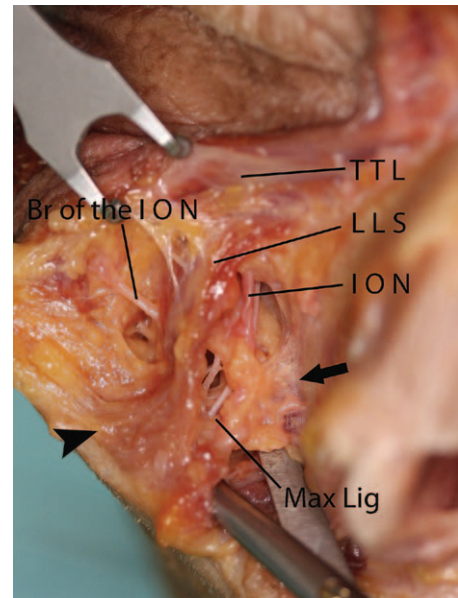


**Fig. 5.** Viewed from below, this specimen demonstrates the important anatomy in the lateral boundary of the premaxillary space, which separates this space from the prezygomatic space located more laterally. The angular vein runs cephalically toward the upper boundary of the premaxillary space. Branches of the infraorbital nerve (*Br of the ION*) and facial nerve, transitioning to the superficial fascia, are located on either side of the angular vein. *LLS*, levator labii superioris, floor of the premaxillary space.

organs (Fig. 6). The levator labii superioris (floor of the premaxillary space), which originates above the infraorbital foramen, covers the main trunk of the infraorbital nerve as it runs inferiorly over the maxilla. The main trunk runs caudally, with small nerve branches given off laterally and medially. The latter then come to be located in the lateral and medial borders of the premaxillary space as they transition to a more superficial



**Fig. 6.** Branches of the facial nerves (buccal and zygomatic branches) and the infraorbital nerve (*ION*), respectively, running under the zygomaticus major and minor (*Zy Mj & Mi*) and the levator labii superioris (*LLS*). These nerves are protected when utilizing a “through the spaces” dissection approach, as they are located under the floor of the prezygomatic and premaxillary spaces.



**Fig. 7.** The course of the infraorbital nerve (*ION*). The infraorbital nerve emerges from the infraorbital foramen and runs inferomedially, under the protection of the levator labii superioris (*LLS*), which forms the floor of the premaxillary space. Smaller branches from the infraorbital nerve run laterally and medially and transition to the superficial fascia in the lateral and medial (not shown) boundaries of the premaxillary space. Also demonstrated is the osteocutaneous nature of the maxillary ligament (*Max Lig*), originating from the maxilla (*arrow*) and inserting densely into the dermis (*arrowhead*). *TTL*, tear trough ligament.

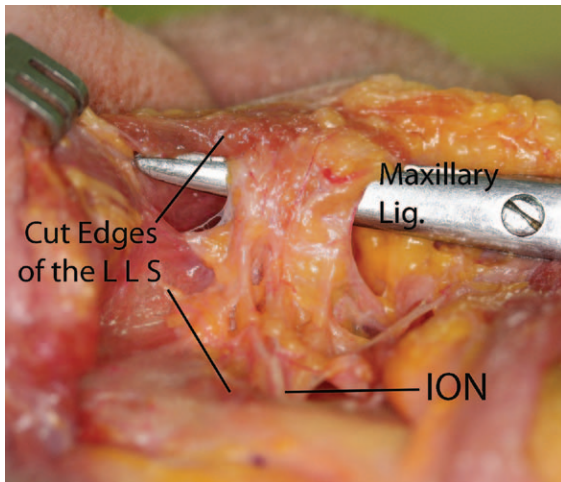
level, as described earlier. The main trunk of the infraorbital nerve runs caudally under the levator labii superioris, and at approximately the level of the alar base (when it reaches the maxillary ligament), it transitions to the subcutaneous plane, in close association with the caudal side of maxillary ligament, to provide sensation to the cheek and upper lip (Figs. 7 and 8).

The anatomy and relations of the premaxillary space are summarized in Figure 9.

## DISCUSSION

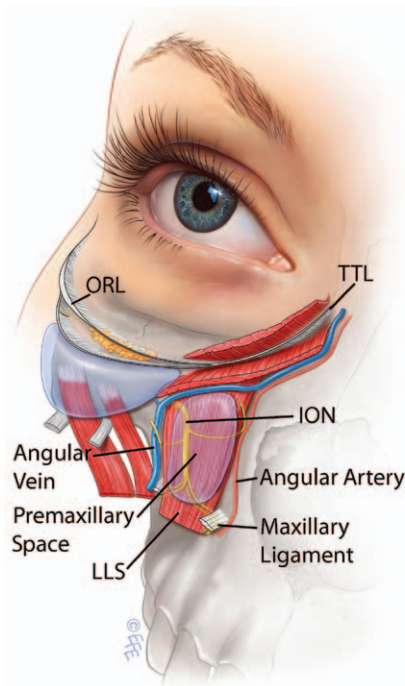
This study defined the premaxillary space, which underlies the upper part of the nasolabial segment overlying the maxilla. This description is significant in that it completes our understanding of the soft-tissue spaces and retaining ligaments and their relations in the midcheek. Anatomically and functionally, the premaxillary space is analogous to the prezygomatic space.<sup>8</sup> Both are located over the midcheek skeleton, the former over the maxilla and the latter over the zygoma. These spaces exist to give the superficial





**Fig. 8.** The specimen demonstrates the main trunk of the infraorbital nerve (*ION*) continuing to the superficial fascia in close association with, and protected by, the maxillary ligament at the inferior boundary of the premaxillary space. *LLS*, levator labii superioris.

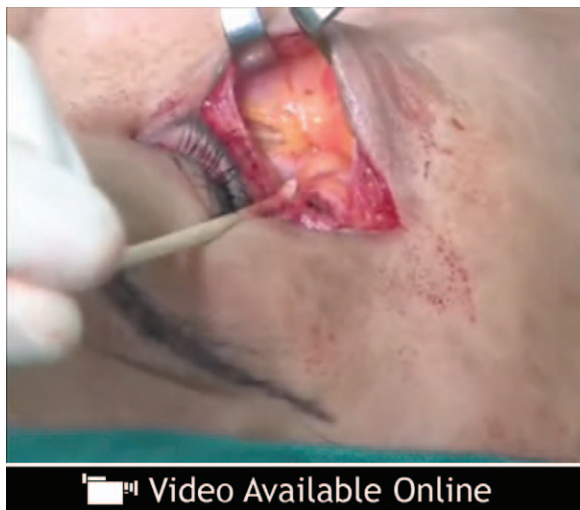fascia independent mobility over the deep fascia. This arrangement allows the sphincteric muscle of the lower lid, the orbicularis oculi (which forms the roof of both spaces), to function independently of the lip elevators (the zygomaticus



**Fig. 9.** The anatomy and key relations of the premaxillary space. *LLS*, levator labii superioris; *ION*, infraorbital nerve; *TTL*, tear trough ligament; *ORL*, orbicularis retaining ligament. Reprinted with permission from Dr. Levent Efe.

major and minor in the floor of the prezygomatic space and the levator labii superioris in the floor of the premaxilla space). The sub-superficial musculoaponeurotic system spaces separate the two bony cavities of the face, the orbit above and the oral cavity below, thereby also functioning to limit the effects of the sphincteric orbicularis oculi and orbicularis oris to the periorbital and perioral areas, respectively.<sup>2</sup> Strong retaining ligaments are strategically located above and below these two spaces to support the soft tissues around these cavities. The tear trough-orbicularis retaining ligament (which forms the superior border of both the premaxillary and prezygomatic spaces) is the key ligament that supports the periorbital soft tissues. Similarly, the maxillary and zygomatic ligaments, located near the inferior edges of the maxilla and the zygoma, are strategically located to provide support for the soft tissues over the vestibule of the oral cavity. The ligament located at the inferior part of the maxilla has previously been referred to as the buccal maxillary ligament.<sup>10</sup> For consistency and to avoid confusion, the term maxillary ligament was used here. This article, however, is the first to describe in detail the dimensions and relations of the maxillary ligaments. The nerves, both motor (facial nerve branches) and sensory (zygomaticofacial and infraorbital nerves), are located in close association with the retaining ligaments, which provide protection and support as the nerves pass from deep to superficial to their target tissues.

Surgically, utilizing the three soft-tissue spaces of the midcheek (preseptal space above and below the prezygomatic space laterally and premaxillary space medially) provides safe composite (preperiosteal) access to the midcheek to achieve a true midcheek mobilization<sup>15</sup> (see **Video, Supplemental Digital Content 2**, which demonstrates the use of facial soft-tissue spaces of the midcheek to safely and effectively access the midcheek, <http://links.lww.com/PRS/A741>). The prerequisite for effective lifting or repositioning of the superficial composite is the adequacy of surgical release of the retaining ligaments.<sup>11</sup> Otherwise, the restraining effect of the ligaments would limit the benefits of tissue lifting to only within the boundaries of that particular space. The major point of fixation is the tear trough-orbicularis retaining ligament complex. This structure is the common boundary of all three midcheek spaces and corresponds to the convergent point on the Y-shaped groove seen on the surface. Accordingly, complete release of



**Video 2.** Supplemental Digital Content 2 demonstrates the use of facial soft-tissue spaces of the midcheek to safely and effectively access the midcheek, <http://links.lww.com/PRS/A741>. The use of this anatomy in the midcheek lift is demonstrated here.

the tear trough–orbicularis retaining ligament eliminates the tethering that separates the three segments and, importantly, allows the malar segment and the nasolabial segment to lift with elevation of the orbicularis oculi.<sup>12</sup>

The tear trough–orbicularis retaining ligament complex needs to be sharply released to a significantly greater extent than is generally appreciated because of its diffuse area of origin [about 8 mm of orbicularis origin (with the tear trough ligament sandwiched between the origins of the orbicularis oculi) medially, 4 mm centrally, and up to 7 mm laterally] (Fig. 1). Complete release is confirmed when the fibers of the levator labii superioris (whose fibers have a different orientation and do not tent on lifting the orbicularis) in the floor and the sub–orbicularis oculi fat (in the roof) are visualized beyond the released muscle edge. Importantly, dissection should be performed close to the maxilla with gentle upward traction on the orbicularis oculi. This is because the angular vein and the small nerve branches associated with it are located on the underside of the orbicularis oculi (at the upper boundary of the premaxillary space). The angular vein should be identified and gently retracted before gaining full access to the premaxillary space. This anatomy signals that the premaxilla space has been entered and hence the origin of the orbicularis oculi is completely released. The middle and lateral ligamentous part of the orbicularis retaining ligament likewise needs to be sharply released, as doing so brings the dissection into the prezygomatic space. The zygomaticofacial nerve, located laterally

emerging from the body of the zygoma, is situated at the superior boundary of the prezygomatic space.<sup>8</sup> Therefore, seeing the nerve would herald impending entrance into the prezygomatic space. With complete release of the orbicularis retaining ligament, one would note the significant elevation of the malar and nasolabial segments with traction on the orbicularis oculi muscle. Once the premaxillary and prezygomatic spaces are entered, they can be bluntly opened to their inferior boundaries.

The risk of injuring the infraorbital nerve has been a concern with the preperiosteal approach to the midcheek and in part accounts for the preference for subperiosteal dissection in the midcheek.<sup>13,14</sup> Utilizing the premaxillary space completely avoids this occurrence, as the nerve is anatomically covered and protected by the levator labii superioris, which forms the floor of the space until it transitions to the superficial tissues in association with the maxillary ligaments at the inferior boundary of the space. The *main infraorbital nerve trunk is never seen* with this approach, provided the inferior boundary is not breached and the floor of the space is protected.

## CONCLUSIONS

1. This article defines the anatomy of the premaxillary space, a true soft-tissue space located under the nasolabial segment of the midcheek. With this description, the three soft-tissue spaces of the midcheek (the preseptal, prezygomatic, and premaxillary spaces), which underlie the three midcheek segments (the lid-cheek, malar, and nasolabial segments), are completely defined.
2. Understanding the anatomy of the spaces and retaining ligaments and their relations to the motor and sensory nerves as well as blood vessels gives the surgeon the ability and confidence to operate safely and effectively in the sub–superficial musculoaponeurotic system plane in the midcheek.
3. The detailed description of the relations of all the midcheek soft-tissue spaces is clinically important, as these spaces provide an “ideal” dissection plane because they are anatomically “predissected” and therefore provide a bloodless and atraumatic access to the midcheek.
4. Precise and complete release of the key retaining ligament of the midcheek, the tear trough–orbicularis retaining ligament complex, is a prerequisite for effective lifting of

the midcheek, including correction of the tear trough deformity.

**Chin-Ho Wong, M.R.C.S. (Ed.), F.A.M.S. (Plast. Surg.)**

W Aesthetic Plastic Surgery  
No. 08–42, Mount Elizabeth Novena Specialist Center  
38 Irrawaddy Road  
329563, Singapore  
wchinho@hotmail.com

### PATIENT CONSENT

*The patient provided written consent for use of the images.*

### ACKNOWLEDGMENTS

*This study was funded in part by Singhealth Foundation Research Grant SHF/FG409S/2009. The authors acknowledge the enthusiasm and hard work of Drs. Terence Goh, Jonah Kua, Adrian Ooi, and Michael Hsieh during the dissections and video production. They also thank Dr. Zayer Min and the staff at the Clinical Skills Laboratory, Singhealth Academy, for assistance with this project.*

### REFERENCES

- Mendelson BC, Jacobson SR. Surgical anatomy of the midcheek: Facial layers, spaces, and the midcheek segments. *Clin Plast Surg.* 2008;35:395–404; discussion 393.
- Mendelson BC. Facelift anatomy, SMAS retaining ligaments and facial spaces. In: Aston SJ, Steinbrech DS, Walden JL (eds), *Aesthetic Plastic Surgery*. Saunders Elsevier: 2009:53–72.
- Furnas DW. The retaining ligaments of the cheek. *Plast Reconstr Surg.* 1989;83:11–16.
- Stuzin JM, Baker TJ, Gordon HL. The relationship of the superficial and deep facial fascias: Relevance to rhytidectomy and aging. *Plast Reconstr Surg.* 1992;89:441–449; discussion 450.
- Moss CJ, Mendelson BC, Taylor GI. Surgical anatomy of the ligamentous attachments in the temple and periorbital regions. *Plast Reconstr Surg.* 2000;105:1475–1490; discussion 1491.
- Mendelson BC, Freeman ME, Wu W, Huggins RJ. Surgical anatomy of the lower face: The premasseter space, the jowl, and the labiomandibular fold. *Aesthetic Plast Surg.* 2008;32:185–195.
- Muzaffar AR, Mendelson BC, Adams WP Jr. Surgical anatomy of the ligamentous attachments of the lower lid and lateral canthus. *Plast Reconstr Surg.* 2002;110:873–884; discussion 897.
- Mendelson BC, Muzaffar AR, Adams WP Jr. Surgical anatomy of the midcheek and malar mounds. *Plast Reconstr Surg.* 2002;110:885–896; discussion 897.
- Wong CH, Hsieh M, Mendelson BC. The tear trough ligament: The anatomical basis for the tear trough deformity. *Plast Reconstr Surg.* 2012;129:1392–1402.
- LaTrenta G. *The Aesthetic Anatomy of the Face: Atlas of Aesthetic Face and Neck Surgery*. Philadelphia: W B Saunders; 2004:2–44.
- Mendelson BC. Surgery of the superficial musculoaponeurotic system: Principles of release, vectors, and fixation. *Plast Reconstr Surg.* 2001;107:1545–1552; discussion 1553.
- Schiller JD. Lysis of the orbicularis retaining ligament and orbicularis oculi insertion: A powerful modality for lower eyelid and cheek rejuvenation. *Plast Reconstr Surg.* 2012;129:692e–700e.
- Hester TR Jr, Codner MA, McCord CD, Nahai F, Giannopoulos A. Evolution of technique of the direct transblepharoplasty approach for the correction of lower lid and midfacial aging: Maximizing results and minimizing complications in a 5-year experience. *Plast Reconstr Surg.* 2000;105:393–406; discussion 407.
- Hester T, Codner M, McCord C. The “centrofacial” approach for correction of facial aging using the transblepharoplasty subperiosteal cheeklift. *Aesthet Surg J.* 1996;16:51.
- Hamra ST. The zygorbicular dissection in composite rhytidectomy: An ideal midface plane. *Plast Reconstr Surg.* 1998;102:1646–1657.

## Advertising in *Plastic and Reconstructive Surgery*®

Please direct all inquiries regarding advertising in *Plastic and Reconstructive Surgery*® to:

Christopher J. Ploppert  
Advertising Representative  
Lippincott Williams & Wilkins  
Two Commerce Square  
2001 Market Street  
Philadelphia, PA 19103  
Tel: 215-521-8429  
Fax: 215-827-5809  
Email: christopher.ploppert@wolterskluwer.com